

CASE REPORT

Gynecologic Surgery

Retained abdominal retractor blade - an unusual cause of chronic pelvic pain: A case report

Joy K. Ngoloma^{1*}, Philomena A. Owende², Benjamin O. Elly³

¹ Department of Obstetrics and Gynecology, University of Nairobi, Nairobi, Kenya

² Department of Obstetrics and Gynecology, Kenyatta National Hospital, Nairobi, Kenya

³ Department of Obstetrics and Gynecology, Kenyatta University, Nairobi, Kenya

*Correspondence: jkngoloma@gmail.com

Received: 12 March 2022; Revised: 21 June 2022; Accepted: 24 June 2022; Available online: June 2022

Copyright © 2022, The authors. Published by JOGECA. This is an open access article under the terms of the Creative Commons Attribution 4.0 International License (<http://creativecommons.org/licenses/by/4.0/>), which permits unrestricted reuse, distribution, and reproduction in any medium provided the original author(s) and the source are properly cited.

Abstract

Background: Retained foreign objects (RFOs) are surgical items that are unintentionally retained within the patient's body after a surgical procedure and are associated with morbidity, mortality and medicolegal ramifications.

Case presentation: A 48-year-old para 3+0 presented to the gynecology clinic with a long-standing history of nonspecific symptoms following hysterectomy performed 22 months earlier. Examination findings and imaging studies were unremarkable. Diagnostic

laparoscopy revealed a retained retractor blade overlying the sigmoid colon. The symptoms resolved after removal, and the patient was discharged on the second postoperative day.

Conclusion: Retained foreign objects often result in nonspecific symptoms and may be missed on imaging leading to diagnostic challenges. A high suspicion index is required to diagnose RFOs.

Keywords: chronic pelvic pain, hysterectomy, laparoscopy, retained foreign objects

Introduction

Retained foreign objects (RFOs) are surgical items that are unintentionally retained within the patient's body after a surgical procedure (1). RFOs can be gauzes, needles, blades, instruments, or items such as drains and guide wires (1). These are preventable surgical complications that result in high morbidity and mortality (2). The incidence of RFOs is 0.3-1.0 per 1000 abdominal surgeries (1). RFOs account for 69% of reinterventions following surgical procedures (3). Cases of RFOs are underreported owing to the legal and professional consequences (1,4). This is a case of a 48-year-old woman who was found to have a retained retractor blade during laparoscopic evaluation for posthysterectomy chronic pelvic pain.

Case presentation

A 48-year-old para 3+0 presented to the gynecology clinic at Kenyatta National Hospital (KNH) with a long-standing history of abdominal pain associated with dyschezia, tenesmus, and rectal pain. She had undergone total abdominal hysterectomy (TAH) 22 months before due to symptomatic uterine fibroids. The hysterectomy was straightforward and uneventful. The abdominal pain began soon after the TAH; it was intermittent and aggravated by lying on either side, worse at night and had no relieving factors. It was mainly in the suprapubic region but would migrate to the left or right lower quadrant depending on the side she was lying on. There was no associated hematochezia, change in

bowel habits, or weight loss. There were no urinary symptoms. She had been seen at the gynecology clinic on three occasions after the TAH with similar complaints and rectal pain. She was managed with analgesics and antibiotics during these visits. An abdominopelvic ultrasound performed in a previous visit was routine except for minimal right adnexal fluid, which was considered physiological (Figure 1). A decision to perform a diagnostic laparoscopy was made. On admission, her general examination was unremarkable. An abdominal examination revealed tenderness in the left lower quadrant. There was no palpable mass. Both the pelvic examination and digital rectal examination were unremarkable.

A gastroenterology review was done, and the decision to perform a diagnostic laparoscopy was upheld, following which the patient was referred to the gastroenterology clinic for further evaluation. An abdominopelvic ultrasound was requested and was found to be essentially normal. During laparoscopy, a foreign body (blade of a self-retaining retractor) was found adjacent to the left ovary and overlying the sigmoid colon. There was minimal fluid in the left paracolic gutter and a left ovarian cyst. Bilateral salpingectomy and left ovarian cystectomy were performed. A mini-laparotomy was performed to remove the foreign body (Figure 2). An incisional hernia and adhesions were noted on the anterior abdominal wall. Herniorrhaphy was performed, after which the abdomen was closed in layers. She progressed well postoperatively and was discharged on the second postoperative day.

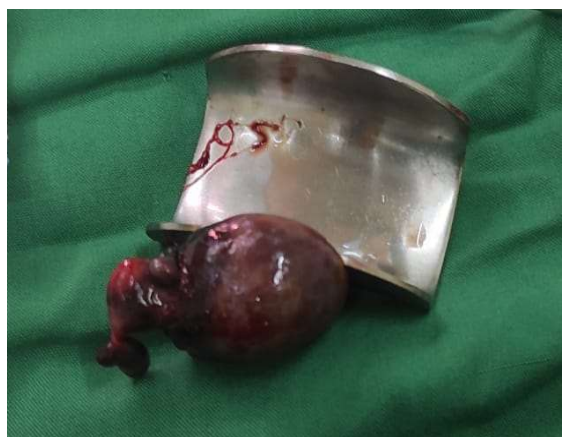

Figure 2: Abdominal retractor blade recovered during the laparotomy.

Discussion

RFOs are highest in abdominal, pelvic, and chest surgical procedures (5). Risk factors associated with RFOs include emergency procedures,

changeover of theater staff during the procedure, fatigue among healthcare workers, long procedures, procedures done at night, and patients with high body mass indices (BMI) (3,4,6). Retained surgical instruments can result in complications such as pain, sepsis, bowel perforation, and death (2). RFOs often pose diagnostic challenges due to the nonspecific symptoms associated with them. In this case, the patient presented with nonspecific symptoms, such as abdominal pain associated with dyschezia and tenesmus. In addition, RFOs may occasionally be missed on imaging. The patient presented here had two negative abdominopelvic ultrasound scans. Imaging modalities used to diagnose RFOs are plain X-ray, ultrasound, computed tomography (CT) scan, magnetic resonance imaging (MRI), and fluoroscopy (7).

A high index of suspicion for RFOs is required in patients with pain, infection, or a palpable mass following surgery where other causes have been ruled out. Counting of gauzes, needles, and instruments should be done before a surgical procedure, before the closure of a body cavity, and before skin closure to prevent RFOs (1). The World Health Organization (WHO) surgical safety checklist is a valuable tool that should be used in every procedure (8). The checklist is simple to use and can be completed within a short time. It consists of three components: sign in, time out and sign out, completed before the induction of anesthesia, before skin incision, and before the patient leaves the operating room, respectively. The use of the checklist has reduced surgical complications, reinterventions, infections, and death by 36%, 25%, 50%, and 47%, respectively (8). However, inaccurate counts have been reported for most RFO cases (3). This can be attributed to human error. Newer modalities such as barcodes and radiofrequency identification microchips can significantly improve the identification of misplaced RFOs (9,10).

Conclusion

Retained foreign objects often result in nonspecific symptoms and may be missed on imaging leading to diagnostic challenges. A high suspicion index is required to diagnose RFOs.

Consent for publication

Informed consent for publication was obtained from the patient.

Acknowledgement

The authors thank the patient for consenting to publish this case report.

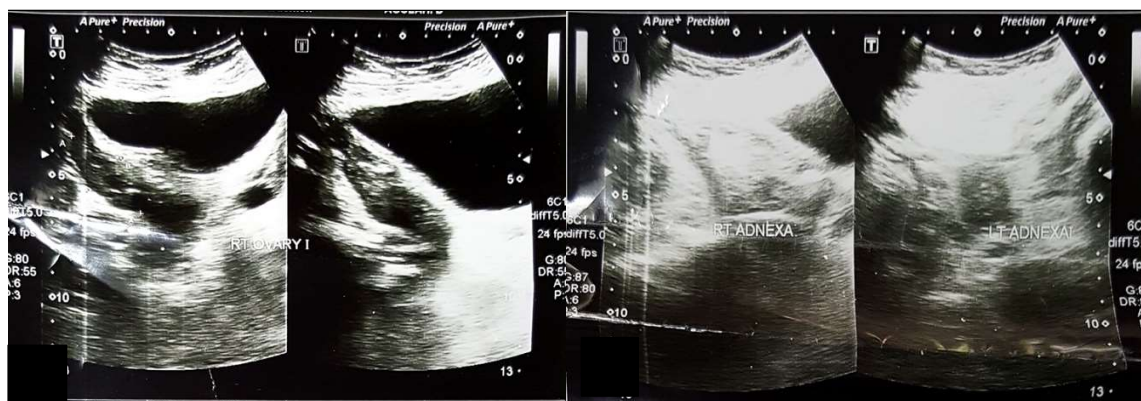


Figure 1: A and B: Ultrasound scan images demonstrating the left and right adnexa, respectively.

Declarations

Conflict of interests

The authors declare no conflicts of interest.

Funding

None

References

1. Zejnullahu VA, Bicaj BX, Zejnullahu VA, Hamza AR. Retained Surgical Foreign Bodies after Surgery. *Open Access Maced J Med Sci*. 2017;5(1):97-100. doi:10.3889/oamjms.2017.005
2. Gavrić Lovrec V, Cokan A, Lukman L, Arko D, Takač I. Retained surgical needle and gauze after cesarean section and adnexectomy: a case report and literature review. *J Int Med Res*. 2018;46(11):4775-4780. doi:10.1177/0300060518788247
3. Gawande AA, Studdert DM, Orav EJ, Brennan TA, Zinner MJ. Risk factors for retained instruments and sponges after surgery. *N Engl J Med*. 2003;348(3):229-235. doi:10.1056/NEJMsa021721
4. Kaiser CW, Friedman S, Spurling KP, Slowick T, Kaiser HA. The retained surgical sponge. *Ann Surg*. 1996;224(1):79-84. doi:10.1097/0000658-199607000-00012
5. Mashhadi MR, Shahabinejad M. Twenty Years with a Retained Foreign Body after Hysterectomy: A Case Report. *Adv J Emerg Med*. 2019;3(3):e29. Published 2019 Apr 6. doi:10.22114/ajem.v0i0.139
6. Egorova NN, Moskowitz A, Gelijns A, et al. Managing the prevention of retained surgical instruments: what is the value of counting?. *Ann Surg*. 2008;247(1):13-18. doi:10.1097/SLA.0b013e3180f633be
7. Stawicki SP, Cook CH, Anderson HL 3rd, et al. Natural history of retained surgical items supports the need for team training, early recognition, and prompt retrieval. *Am J Surg*. 2014;208(1):65-72. doi:10.1016/j.amjsurg.2013.09.029
8. Haynes AB, Weiser TG, Berry WR, et al. A surgical safety checklist to reduce morbidity and mortality in a global population. *N Engl J Med*. 2009;360(5):491-499. doi:10.1056/NEJMsa0810119
9. Greenberg CC, Diaz-Flores R, Lipsitz SR, et al. Bar-coding surgical sponges to improve safety: a randomized controlled trial. *Ann Surg*. 2008;247(4):612-616. doi:10.1097/SLA.0b013e3181656cd5
10. Macario A, Morris D, Morris S. Initial clinical evaluation of a handheld device for detecting retained surgical gauze sponges using radiofrequency identification technology. *Arch Surg*. 2006;141(7):659-662. doi:10.1001/archsurg.141.7.659