

CASE REPORT

Family Planning and Contraception

## A fatal outcome following complications of multiple blind attempts of removal of a displaced intrauterine device: A case report

Ernesto M. Lungena<sup>1\*</sup>, Joy K. Ngoloma<sup>1</sup>, Yusuf A. Khalil<sup>1</sup>, Frederick K. Omanwa<sup>1</sup>

<sup>1</sup> Department of Obstetrics and Gynecology, University of Nairobi, Nairobi, Kenya

\*Correspondence: [ernestmiji@gmail.com](mailto:ernestmiji@gmail.com)

Received: 13 July 2022; Revised: 2 October 2022; Accepted: 4 October 2022; Available online: October 2022

Copyright © 2022, The authors. Published by JOGECA. This is an open access article under the terms of the Creative Commons Attribution 4.0 International License (<http://creativecommons.org/licenses/by/4.0/>), which permits unrestricted reuse, distribution, and reproduction in any medium provided the original author(s) and the source are properly cited.

### Abstract

**Background:** Intrauterine devices (IUDs) are long-acting reversible contraceptives that are widely used due to their effectiveness and safety profile. Complications associated with IUD insertion or removal are rare but can be fatal.

**Case presentation:** A 36-year-old para 3+0 presented to the accident and emergency department with per vaginal bleeding and signs of an acute abdomen following three failed attempts to remove an IUD inserted two weeks prior. Ultrasound imaging revealed marked hemoperitoneum, and an IUD embedded in the left ovary. An exploratory laparotomy revealed that the IUD was embedded on

the left ovary with multiple perforations on the uterus and ileum. The IUD was removed, and the perforations were repaired. Her condition deteriorated and she succumbed to refractory septic shock two days later.

**Conclusion:** The presented patient succumbed to complications resulting from injuries caused by an IUD. Blind procedures to remove displaced IUDs should be avoided especially where previous attempts have failed.

**Keywords:** intrauterine device, ovarian embedment, uterine perforation

### Introduction

Intrauterine devices (IUDs) are long-acting reversible contraceptives that are widely used due to their effectiveness and safety profile (1). According to the Kenya Demographic Health Survey 2014, 3.4% of married women in Kenya use IUDs for contraception (2). The two main types of IUDs are intrauterine copper devices and levonorgestrel IUDs. IUDs are generally safe but can result in various complications (1). This is a case of a 36-year-old who presented with features of an acute abdomen following multiple blind attempts to retrieve a displaced IUD. Ovarian embedment of the IUD and multiple uterine and ileal perforations were demonstrated on exploratory laparotomy.

### Case presentation

A 36-year-old para 3+0 presented to the accident and emergency department at the Kenyatta National Hospital (KNH) with a one-week history of bleeding per vagina. She had been delivered via cesarean section in the background of preeclampsia with severe features three months before. An IUCD had been inserted in a peripheral facility two weeks before her current presentation. She developed persistent per vagina bleeding a week after the IUCD insertion. Pelvic ultrasound revealed a displaced IUCD embedded within the myometrium. Removal of the IUCD via alligator forceps was attempted three times; once in a peripheral facility and twice at KNH. The last attempt was made two days before her current presentation to the accident and emergency

department at KNH. The last attempt was followed by severe abdominal pain, vomiting, and per vaginal bleeding. There was no associated abdominal distension or malodorous per vaginal discharge.

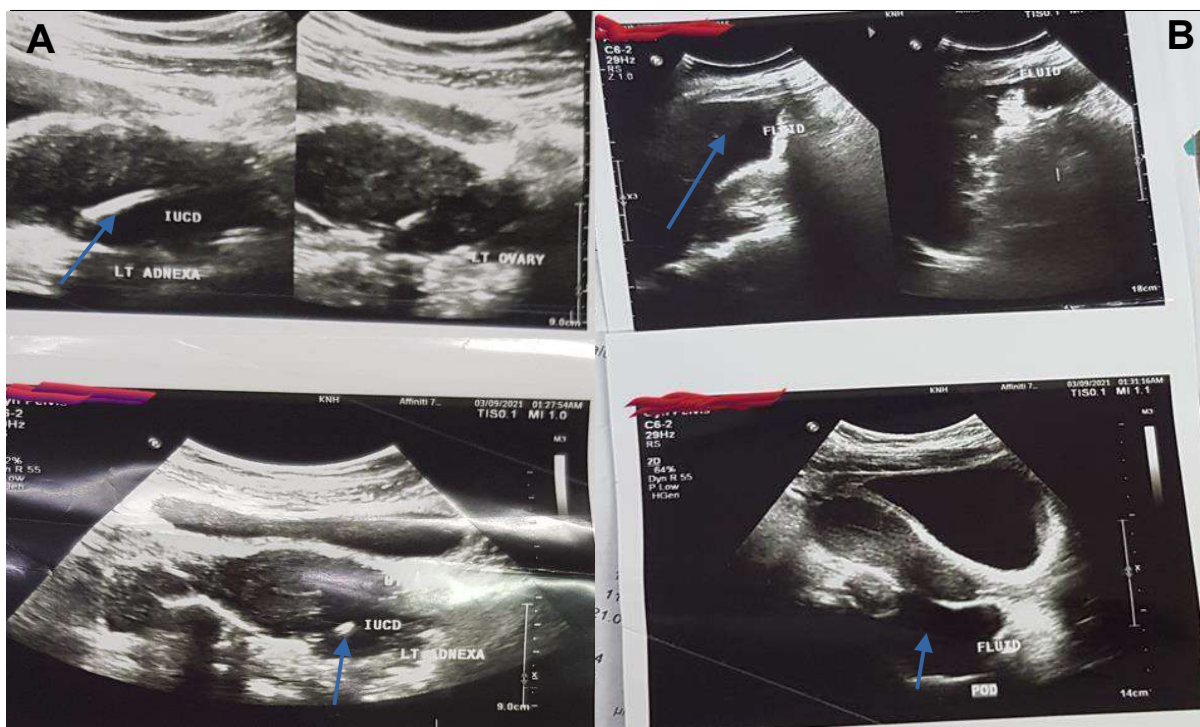
On admission, she was sick looking and clinically afebrile. She had marked abdominal tenderness. She had mild per vaginal bleeding on speculum examination. Paracentesis was negative. Her blood pressure was 111/58mmHg and a pulse rate of 110 beats per minute. A pelvic ultrasound showed a marked hemoperitoneum and a displaced IUCD at the left adnexa adjacent to the left ovary (Figure 1). She was scheduled for an emergency exploratory laparotomy. On arrival at the theater, her blood pressure was unrecordable, and her pulse rate was 152 beats per minute. Intraoperatively, multiple uterine perforations were found at the fundus, anterior aspect of the uterine corpus, and the level of the internal os. A 5cm laceration on the anterior aspect of the uterine corpus that involved two subserosal fibroids each with a diameter of 2cm was demonstrated. The fibroids were actively bleeding. IUCD was found embedded in the left ovary. Lacerations on the left ovary were also observed and collection of 250ml pus within the peritoneal cavity. Two antimesenteric perforations 70-80cm from the ileocecal junction, each measuring 1cm and 5cm apart were also seen. Removal of the IUCD, myomectomy, uterine repair, resection and anastomosis, and abdominal lavage were done (Figure 2). A drain was left in

situ. She was transfused with three units of blood intraoperatively.

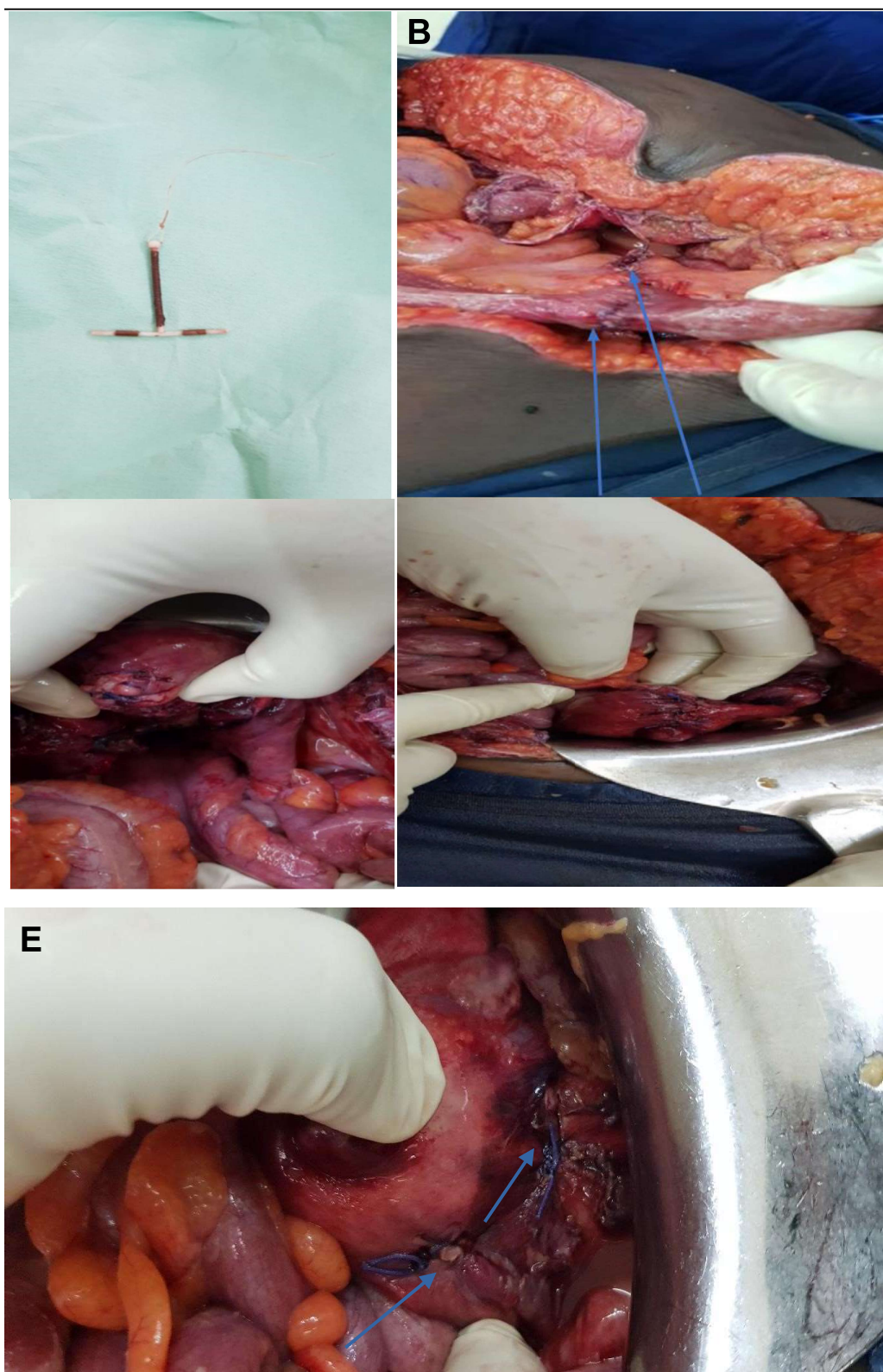
The patient was noted to be desaturating three days postoperatively. Her oxygen saturation was 89% on room air and 92% on oxygen. Her level of consciousness was altered, with a Glasgow coma scale of 12/15. Her abdomen was distended. On respiratory examination, she had bilateral rhonchi and crepitation on both lower zones. Abdominal ultrasound was unremarkable. She developed septic shock two days later and was transferred to the critical care unit. The drain was still active, and the incision site also had a minimal discharge. Repeat exploratory laparotomy was performed two days later found no intraabdominal fluid collection. The patient's condition deteriorated postoperatively, and she started vomiting one day later. Fecal matter was recovered in the vomitus as well as the abdominal drain effluent. An exploratory laparotomy was performed a day later during which anastomotic leaks were demonstrated in the ileum. Her condition worsened postoperatively, and she was certified dead the following day.

### Discussion

Intrauterine device use can be discontinued in the event of side effects, including pain and heavy menstrual bleeding (3). Complications associated with IUDs include missing strings, expulsion, contraceptive failure, and perforation of the uterus or adjacent organs (1,4). Uterine perforation is a



**Figure 1: A:** Ultrasound scan demonstrating displaced intrauterine copper device (IUCD) at the left adnexa (arrows); **B:** Ultrasound scan demonstrating hemoperitoneum (arrows).



**Figure 2:** A: IUCD removed from the left ovary; B: Terminal-terminal intestinal anastomosis after resection (arrows); C and D: Uterine fundal posterior wall perforations after repair (arrows); E: Anterior uterine wall perforations (arrow).

rare complication of IUDs with an incidence of 1 in 1000 (5). Perforation mainly occurs during the insertion procedure, and patients may be

asymptomatic, and the symptoms may take days to years to manifest (1,4). Abdominal pain or bleeding soon after insertion of an IUD should

raise the suspicion of uterine perforation (6). Here, the patient developed bleeding a week after the insertion of the IUD and opted to have it removed due to persistent bleeding.

The risk factors that predispose one to uterine perforation include inexperience of the healthcare provider, retroverted uterus, nulliparity, lactation, previous miscarriages, uterine abnormalities, and IUD type (7). IUD migration and uterine perforation are more common in individuals with uterine fibroids, as was in this case (4). IUDs can cause injuries to other organs after perforating the uterus, particularly to the sigmoid colon, small intestine, and rectum (8). The patient, in this case, was found to have ileal perforations. Ovarian transmigration of IUDs is extremely rare, mainly because of the ovarian capsule (9). Very few cases have been reported globally. Imaging studies to locate a lost IUD include ultrasound, plain radiography, and computed tomography scan (6,8). Hysteroscopy and laparoscopy are useful for the diagnosis and removal of misplaced IUDs (6). Removal of misplaced IUDs is often done as a blind procedure using alligator forceps, artery forceps, or hooks. However, hysteroscopy is a safe option that precludes the need for major surgery to retrieve misplaced IUDs (10). Here, the patient underwent three blind attempts to remove the IUCD and this led to several complications, eventually resulting in her death.

### Conclusion

Intrauterine devices are generally safe but can lead to several complications. The presented patient succumbed to complications resulting from injuries caused by an IUD. Blind procedures to remove displaced IUDs should be avoided especially where previous attempts have failed.

### Consent for publication

Informed consent for publication was obtained from the patient's next of kin.

### Declarations

### Conflict of interests

The authors declare no conflicts of interest.

### Funding

None

### References

1. Kho KA, Chamsy DJ. Perforated intraperitoneal intrauterine contraceptive

devices: diagnosis, management, and clinical outcomes. *J Minim Invasive Gynecol.* 2014;21(4):596-601. doi:10.1016/j.jmig.2013.12.123

2. Kenya National Bureau of Statistics, Ministry of Health/Kenya, National AIDS Control Council/Kenya, Kenya Medical Research Institute, National Council for Population and Development/Kenya, and ICF International. 2015. Kenya Demographic and Health Survey 2014. Rockville, MD, USA: Kenya National Bureau of Statistics, Ministry of Health/Kenya, National AIDS Control Council/Kenya, Kenya Medical Research Institute, National Council for Population and Development/Kenya, and ICF International
3. Grunloh DS, Casner T, Secura GM, Peipert JF, Madden T. Characteristics associated with discontinuation of long-acting reversible contraception within the first 6 months of use. *Obstet Gynecol.* 2013;122(6):1214-1221. doi:10.1097/01.AOG.0000435452.86108.59
4. Disu S, Boret A. Asymptomatic ileal perforation of an intrauterine device. *Arch Gynecol Obstet.* 2004;269(3):230-231. doi:10.1007/s00404-003-0566-x
5. Rowlands S, Oloto E, Horwell DH. Intrauterine devices and risk of uterine perforation: current perspectives. *Open Access J Contracept.* 2016;7:19-32. Published 2016 Mar 16. doi:10.2147/OAJC.S85546
6. Stuckey A, Dutreil P, Aspuru E, Nolan TE. Symptomatic cecal perforation by an intrauterine device with appendectomy removal. *Obstet Gynecol.* 2005;105(5 Pt 2):1239-1241. doi:10.1097/01.AOG.0000157760.59342.bc
7. Carmody K, Schwartz B, Chang A. Extrauterine migration of a mirena® intrauterine device: a case report. *J Emerg Med.* 2011;41(2):161-165. doi:10.1016/j.jemermed.2010.04.024
8. Arslan A, Kanat-Pektas M, Yesilyurt H, Bilge U. Colon penetration by a copper intrauterine device: a case report with literature review. *Arch Gynecol Obstet.* 2009;279(3):395-397. doi:10.1007/s00404-008-0716-2
9. Verma U, Verma N. Ovarian embedding of a transmigrated intrauterine device: a case report and literature review. *Arch Gynecol Obstet.* 2009;280(2):275-278. doi:10.1007/s00404-008-0882-2
10. Asto MRD, Habana MAE. Hysteroscopic-guided Removal of Retained Intrauterine Device: Experience at an Academic Tertiary Hospital. *Gynecol Minim Invasive Ther.* 2018;7(2):56-60. doi:10.41