

CASE REPORT

Pediatric and Adolescent Gynecology

Peritoneal tuberculosis with a frozen abdomen in an adolescent female: A case report

Faustine James^{1*}, Irene N. Kimeu¹, David Jalloh¹, Rose J. Kosgei^{1,2}

¹Department of Obstetrics and Gynecology, University of Nairobi, Nairobi, Kenya

²Department of Obstetrics and Gynecology, Kenyatta National Hospital, Nairobi, Kenya

*Correspondence: phurstyne12@gmail.com

Received: 10 December 2022; Revised: 16 March 2023; Accepted: 17 March 2023; Available online: April 2023

Copyright © 2023, The authors. Published by JOGECA. This is an open access article under the terms of the Creative Commons Attribution 4.0 International License (<http://creativecommons.org/licenses/by/4.0/>), which permits unrestricted reuse, distribution, and reproduction in any medium provided the original author(s) and the source are properly cited.

Abstract

Background: Peritoneal tuberculosis is a rare form of extrapulmonary tuberculosis, which can result from the reactivation of latent foci in the peritoneal cavity.

Case presentation: A 19-year-old female presented to the gynecological oncology clinic with a two-month history of generalized abdominal pain and progressive abdominal distention. An abdominopelvic computed tomography scan revealed a cystic right adnexal lesion with massive simple ascites. A frozen abdomen was noted during exploratory laparotomy. Histological examination of the peritoneal biopsy reported granulomatous

nodules with numerous epithelioid histiocytes. Postoperatively, she was managed with rifampicin, isoniazid, pyrazinamide, ethambutol, and pyridoxine for six months and recovered fully.

Conclusion: Peritoneal tuberculosis may mimic ovarian and peritoneal malignancies. A high suspicion index of peritoneal tuberculosis should be entertained in patients presenting with nonspecific symptoms of ovarian or peritoneal cancers.

Keywords: abdominal distension, extrapulmonary tuberculosis, ovarian malignancy, peritoneal tuberculosis

Introduction

Tuberculosis is an infectious disease caused by *Mycobacterium tuberculosis* (MTB), which commonly presents as a pulmonary disease (1). Extrapulmonary manifestations may result from lymphatic or hematogenous spread. Peritoneal TB is an uncommon presentation of extrapulmonary TB (1). The risk factors for peritoneal TB include poorly controlled diabetes mellitus, underlying malignant conditions, alcoholic liver disease, immunocompromised states, and peritoneal dialysis (1). However, individuals without any of these predisposing factors may still present with peritoneal TB. The pathogenesis of peritoneal TB includes hematogenous spread from primary pulmonary infection or reactivation of latent foci in the peritoneal cavity (2). Clinical presentations of

peritoneal TB are often nonspecific, posing a diagnostic challenge (1). Patients may present with weight loss, fever, abdominal pain, and ascites of insidious onset (2). A frozen abdomen occurs when adhesions develop between the abdominal viscera and the anterolateral abdominal wall. It may result from peritoneal carcinomatosis or after wound dehiscence due to surgical site infection (3). This is a case of peritoneal tuberculosis in an adolescent female who presented with nonspecific symptoms mimicking ovarian cancer.

Case presentation

A 19-year-old female presented to the gynecological oncology clinic at the Kenyatta National Hospital with a two-month history of generalized abdominal pain and progressive abdominal distention. She

gave no history of associated nausea, vomiting, diarrhea, cough, weight loss, prior chronic illness, or surgery. Her menarche was at 13 years, and she reported a regular 28-day cycle. She gave no history of contraceptive use, and she was reportedly not sexually active. On admission, her blood pressure was 121/85mmHg, heart rate 94 beats per minute, and temperature 37.1°C. On clinical examination, the abdomen was globularly distended with an inverted umbilicus. A firm, immobile mass was palpable extending from the suprapubic region to the epigastrium, with mild tenderness on deep palpation and positive fluid thrill without organomegaly. A digital rectal examination revealed a normal anal sphincter tone with free rectal mucosa.

Her preoperative aspartate aminotransferase, total bilirubin, lactate dehydrogenase, and cancer antigen 125 (CA-125) test levels were elevated at 59U/L, 8.4mg/dL, 415IU/L, and 105U/ml, respectively (Table 1). SARS-CoV-2 polymerase chain reaction and HIV serology tests were negative. A pelvic ultrasound scan revealed a nonpregnant uterus with an enlarged right ovary measuring 4.18 x 4.23 x 4.26cm with massive simple ascites (Figure 1). Abdominopelvic computed tomography scan revealed a cystic right adnexal lesion with large ascitic fluid and enhancing peritoneum suggestive of tuberculous peritonitis with a differential diagnosis of peritoneal inclusion cyst or spontaneous bacterial peritonitis. Intraoperatively, the peritoneum was completely frozen (Figure 2), and multinodular lesions covered the intestines, uterus, fallopian tubes, peritoneum, and omentum with dense adhesions (Figure 3). The ovaries were not visualized due to adhesions. Serous ascitic fluid was noted, and incisional biopsy of the peritoneum was taken from the anterior abdominal wall. Peritoneal fluid was aspirated, and a sample was taken for cytology. No areas of caseating necrosis were noted on gross inspection.

The cytological examination reported a population of reactive lymphocytes with occasional plasma cells and histiocytes (reactive lymphocytic effusion). No atypical malignant cells were identified. Microscopy, culture, and antimicrobial sensitivity tests of the peritoneal fluid were negative. Histological examination reported peritoneal adipose tissue exhibiting chronic granulomatous forming nodules with numerous epithelioid histiocytes, some of them multinucleated with necrotic centers, and were surrounded by a cuff of inflammatory cells, mainly lymphocytes (Figure 4,5). Ziehl-Neelsen stain for acid-fast bacilli was negative. These features were suggestive of peritoneal TB. Postoperatively, the patient was started on rifampicin, isoniazid, pyrazinamide, ethambutol, and pyridoxine. She

was discharged after three days in stable condition and was followed up in the general gynecological outpatient clinic. During the first follow-up visit, she reported compliance with the medications. Her abdomen was soft, without palpable masses or areas of tenderness, and a healed subumbilical midline incision scar. She was followed up in three subsequent clinic visits until the completion of the six-month therapy without new complaints and after that followed up in the TB clinic.

Table 1: Preoperative laboratory investigations

Parameter	Reference range	Result
Hemoglobin (g/dl)	9.5-15	13.7
White blood cells (x10 ⁹ /L)	5.6-16.9	6.07
Platelets (x10 ⁹ /L)	150-450	354
Urea (mmol/L)	1.8-7.1	3.26
Creatinine (mmol/L)	52-80	68.1
Alanine transaminase (U/L)	4-36	21
Aspartate aminotransferase (U/L)	8-33	59
Total bilirubin (mg/dl)	0.1-1.2	8.4
Lactate dehydrogenase (IU/L)	105-333	415
Alpha-fetoprotein (IU/ml)	0-5.0	3.83
Carcinoembryonic antigen (ng/ml)	0-5.0	0.78
B-human chorionic gonadotropin (mIU/ml)	55-200	0.1
CA-125 (U/ml)	0-35	105

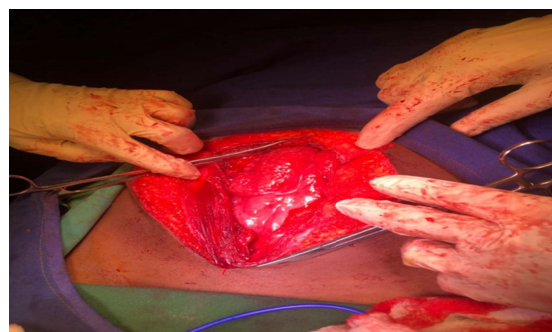


Figure 2: A frozen abdomen was noted during exploratory laparotomy.

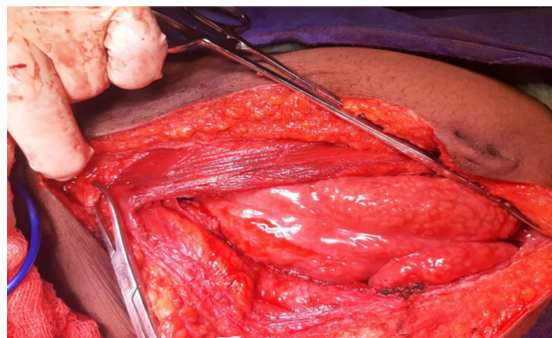


Figure 3: Widespread multinodular lesions covering intraabdominal structures.

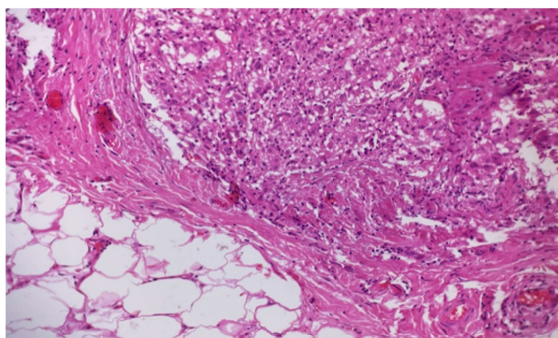


Figure 4: Peritoneal adipose tissue with chronic granulomatous nodules (20X magnification).

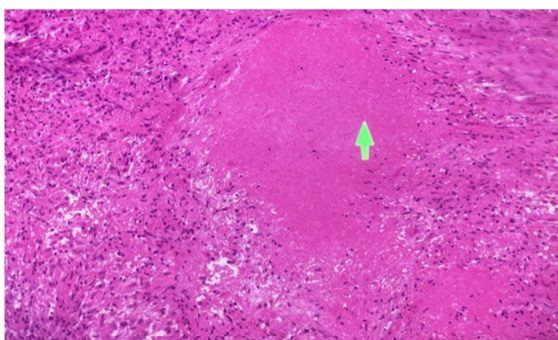


Figure 5: Multinucleated giant cells and epithelioid histiocytes shown with an area of necrosis (20X magnification).

Discussion

Extrapulmonary TB is uncommon. In Kenya, abdominal TB accounts for approximately 3.8% of all extrapulmonary TB cases (4). The reactivation of latent TB may lead to the development of peritoneal TB cases (5). In rare cases of an active pulmonary infection, peritoneal TB may result from the hematogenous spread of the mycobacterium or by direct spread from nearby structures (6,7). Clinical manifestations are often non-specific and variable making timely diagnosis a challenge. Signs and symptoms mostly comprise abdominal pain and distension, fever, fatigue, weight loss, palpable abdominal mass, ascites, and abdominal tenderness (6,8). Similarities in the symptoms of peritoneal TB and abdominal malignancies pose a diagnostic dilemma (7). In extrapulmonary TB, the use of MTB culture is limited due to low bacillary load, hence a negative MTB culture does not rule out the disease. Histopathological studies of peritoneal biopsies can effectively diagnose the disease when caseous necrosis, granulomas, or epithelial cells are reported (9). Here, MTB culture was negative whereas histological examination revealed peritoneal TB. Imaging studies of the abdomen do not differentiate between peritoneal TB and peritoneal carcinomatosis as ascites and peritoneal nodular irregularity may be evident in both cases (8). In the absence of a definitive

diagnosis, response to antituberculous therapy supports a clinical diagnosis of peritoneal TB (1).

Extraovarian pathologies may mimic ovarian malignancies. In the presence of elevated CA-125 and ascites, peritoneal TB can be confused with ovarian malignancy making diagnosis difficult. When peritoneal TB occurs with liver involvement, there is an apparent elevation of tumor markers for gynecological cancers making diagnosis and management complex (2). As in this case, CA-125 levels were elevated with massive ascites, which underpins the diagnostic challenge associated with such a nonspecific presentation. Treatment for uncomplicated cases of peritoneal TB is similar to pulmonary TB. Here, the patient received an initial two months of four-agent antituberculous therapy and an additional four months of double-agent maintenance regimen with full recovery reported after completion of treatment.

Conclusion

Peritoneal tuberculosis may mimic peritoneal and ovarian malignancies. A high suspicion index of peritoneal tuberculosis should be entertained in patients presenting with nonspecific symptoms of ovarian or peritoneal cancers.

Consent for publication

Informed consent for publication was obtained from the patient.

Acknowledgment

Not applicable.

Declarations

Conflict of interests

The authors declare no conflicts of interest.

Funding

None

References

1. Chiew WLA, Liu JXJ, Teo LT. A Rare Case of Peritoneal Tuberculosis. *J. Med. Cases.* 2016;7(4) doi: 10.14740/jmc.v7i4.2449. 130–132-132
2. Yardimci OD, Cetinkaya N, Ozgu E, Oz M, Erkaya S. Tuberculosis in Gynecologic Oncology: Still a Diagnostic Dilemma. *Obstet Gynecol Int J.* 2014;1(2):00012.
3. Kyriazanos ID, Manatakis DK, Stamos N, Stoidis C. Surgical Tips in Frozen Abdomen Management: Application of Coliseum Technique. *Case Rep Surg.* 2015;2015:309290. doi:10.1155/2015/309290

4. Makori, L., Gichana, H., Oyugi, E., Nyale, G., & Ransom, J. (2021). Tuberculosis in an urban hospital setting: Descriptive epidemiology among patients at Kenyatta National Hospital TB clinic, Nairobi, Kenya. *International Journal of Africa Nursing Sciences*, 15, 100308. <https://doi.org/10.1016/j.ijans.2021.100308>
5. Wu DC, Averbukh LD, Wu GY. Diagnostic and Therapeutic Strategies for Peritoneal Tuberculosis: A Review. *J Clin Transl Hepatol*. 2019;7(2):140-148. doi:10.14218/JCTH.2018.00062
6. Jurado LF, Pinzón B, Zandra R, Matijasevic E, del Pilar López-Panqueva R. Peritoneal tuberculosis in a health-care worker, radio-pathological assessment and diagnosis, a case report. *Radiology of Infectious Diseases*. 2019 Dec 1;6(4):163-9
7. Bulut Gökten D, Katipoglu B, Basara E, Ates I, Yılmaz N. A Case Report of Peritoneal Tuberculosis: A Challenging Diagnosis. *Case Rep Infect Dis*. 2018;2018:4970836. Published 2018 Jan 11. doi:10.1155/2018/4970836
8. Alrashed RF, Alkhuwaylidi AA, Aldashash KA, et al. Peritoneal Tuberculosis in a Young Healthy Male Resembling Intra-Abdominal Malignancy. *Cureus*. 2021;13(12):e20677. Published 2021 Dec 25. doi:10.7759/cureus.20677
9. Flores LS, Solís AH, Gutiérrez AE, José LC, Ortiz IC, González HG, Martínez EL, Sabido RC. Peritoneal tuberculosis: A persistent diagnostic dilemma, use complete diagnostic methods. *Revista Médica Del Hospital General De México*. 2015 Apr 1;78(2):55-61