

CASE REPORT

Obstetrics

Metastatic giant pleomorphic retroperitoneal liposarcoma in a pregnant woman with HIV: A case report

Busra A. Ahmed^{1*}, Yusuf A. Khalil¹, Doreen N. Wekesa¹, Onesmus Gachuno¹

¹ Department of Obstetrics and Gynecology, University of Nairobi, Nairobi, Kenya.

*Correspondence: busra07@gmail.com

Received: 28 April 2021; Revised: 10 August 2021; Accepted: 11 September 2021; Available online: October 2021

Copyright © 2021, The authors. Published by JOGECA. This is an open access article under the terms of the Creative Commons Attribution 4.0 International License (<http://creativecommons.org/licenses/by/4.0/>), which permits unrestricted reuse, distribution, and reproduction in any medium provided the original author(s) and the source are properly cited.

Abstract

Background: Liposarcomas and leiomyosarcomas are the most common histological types of retroperitoneal sarcomas, followed by undifferentiated soft tissue sarcomas in adults.

Case presentation: A 38-year-old, gravida 4 para 3 HIV-positive, presented at 13 weeks of gestation to the antenatal ward as a referral with an ultrasound diagnosis of a retroperitoneal mass. Abdominal examination revealed a tender, firm mass in the left upper quadrant, extending to the left flank and fixed to the underlying structures. The abdomen's magnetic resonance imaging revealed a large soft tissue mass in the left retroperitoneum, with local invasion suggestive of a soft tissue sarcoma. She was put on analgesics, antiemetics, intravenous fluids, and total

parenteral nutrition, with a plan for an ultrasound-guided biopsy of the mass and exploratory laparotomy. Her condition deteriorated, and subsequently arrested and succumbed eighteen days postadmission. The histological analysis of the postmortem specimen revealed a pleomorphic metastatic liposarcoma.

Conclusion: Retroperitoneal liposarcomas are rare and often present a diagnostic and treatment challenge. Therefore, a high index of suspicion should be indicated in women who present with abdominal masses.

Keywords: sarcoma, retroperitoneal tumor, pleomorphic liposarcoma, pregnancy, HIV

Introduction

Sarcomas are malignant cancers that originate from skeletal and extraskeletal connective tissues. Although most soft tissue sarcomas occur in the extremities, other sites, including the chest wall, head and neck, the retroperitoneum, and subcutaneous tissues, are also affected (1). Retroperitoneal sarcomas constitute approximately 10-15% of all soft tissue sarcomas. The median age at presentation of retroperitoneal sarcomas is in the fifth decade of life, but they can occur between 16 – 82 years. The male to female ratio is 1:1 (2). Liposarcomas are categorized into five histological subtypes: dedifferentiated, myxoid, round cell, pleomorphic, and well-differentiated (3).

Pleomorphic liposarcoma is an aggressive liposarcoma and a subtype of the retroperitoneal sarcomas. It is rare in pregnancy and often presents a diagnostic and management challenge due to the asymptomatic nature of vague symptoms, mistaken for common pregnancy symptoms (3,4). The human immunodeficiency virus (HIV) infection and the subsequent destruction of T4-positive helper cells are associated with the development of various malignancies. HIV-positive patients have an increased risk of multiple types of cancers because of changes in immune surveillance. In addition to Kaposi sarcoma, leiomyosarcomas and angiosarcomas occur disproportionately in HIV-positive patients (5). A liposarcoma is usually a

malignancy of later life and is rarely encountered in HIV populations. This is a case of an HIV-positive pregnant woman who came with a diagnosis of an abdominal mass; her condition deteriorated, and subsequently arrested and succumbed. A histological diagnosis of a metastatic pleomorphic retroperitoneal liposarcoma was made postmortem.

Case presentation

A 38-year-old, gravida 4 para 3 HIV-positive presented at 13 weeks of gestation to the antenatal ward at the Kenyatta National Hospital (KNH) as a referral with an ultrasound diagnosis of retroperitoneal mass. Her HIV diagnosis was more than ten years, and she was on antiretroviral drugs and reported compliance. The viral load and CD4 count records were not available. On admission, the patient complained of abdominal swelling, which had gradually increased in size over the past month. She reported a loss of appetite, nausea, and postprandial vomiting. Her urinary and bowel movements were regular. She had difficulty in breathing (DIB), which progressively worsened from DIB on exertion to DIB at rest. She was unable to walk due to left hip joint pain, which radiated to the left flank. She had been treated and completed therapy for pulmonary tuberculosis three months before the current presentation.

On physical examination, the patient appeared unwell and was thin, pale, and dehydrated. She was also in respiratory distress, with an oxygen saturation of 99% on five liters of oxygen with a non-rebreather mask. The abdominal examination revealed a tender, firm mass in the left upper quadrant fixed to the underlying structure, nonmoving with respiration, non-ballotable, and measured 20 × 15 cm (Figure 1). The mass extended to the left flank. The splenic notch was absent. The respiratory examination revealed bilateral basal crepitations. Her full blood count, coagulation profile, liver, and renal function tests were unremarkable. Her 24-hour urinary cortisol levels were elevated at 911.2 nmol/L. The chest X-ray was normal. Abdominal magnetic resonance imaging (MRI) revealed a large soft tissue mass that measured 20 × 22 × 23 cm in the left retroperitoneum, with local invasion suggestive of a soft tissue sarcoma. The mass compressed and displaced the left kidney antero-inferiorly, with partial infiltration of the renal parenchyma. It crossed the midline, stretching outward and encasing the left renal vessels. The aorta and its branches were slightly displaced, and there was focal infiltration of the left posterior abdominal wall, with associated subcutaneous edema (Figure 2). The pelvic MRI revealed mild ascites and a gravid uterus (Figure 3).

The patient was managed by a multidisciplinary team comprised of fetomaternal medicine specialists, gynecologic oncologists, general surgeons, urologists, interventional radiologists, and nutritionists. She was put on analgesics, antiemetics, intravenous fluids, and total parenteral nutrition, with a plan for ultrasound-guided biopsy of the mass for histopathological diagnosis and exploratory laparotomy. However, she was hemodynamically unstable. Her condition deteriorated, and subsequently arrested and succumbed eighteen days postadmission. During the postmortem, the fetus protruded from the vagina, with a crown-rump length of 10 cm. It was noted that she was expelled after resuscitative efforts. The abdomen contained peritoneal nodules and omental caking and an estimated 1500mls of straw-colored peritoneal fluid. The nodules had a cheese-like appearance. The lungs were edematous. The histological analysis of the autopsy specimen reported a tumor in the omentum, dispersed in sheets of pleomorphic lipoblastic cells and numerous mitotic figures. A histological diagnosis of metastatic liposarcoma was made.

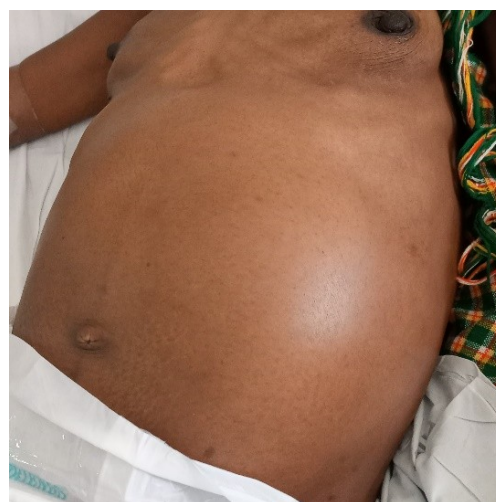

Figure 1: Massive abdominal distension due to a giant mass.

Discussion

The prognosis of liposarcoma is determined by its histological subtype, resection margin, contiguous organ resection, and the patient's age (2,6). Primary retroperitoneal pleomorphic liposarcomas are extremely rare, remarkably chemoresistant, and associated with a significantly lower overall survival rate than other liposarcomas (7). Liposarcomas are usually asymptomatic and are often detected after they increase in size (8). The diagnosis of liposarcoma during pregnancy is incidental during an abdominal or pelvic ultrasound examination (9). In this case, the patient presented at an advanced stage with symptoms for only one month. The appropriate diagnostic and therapeutic approaches

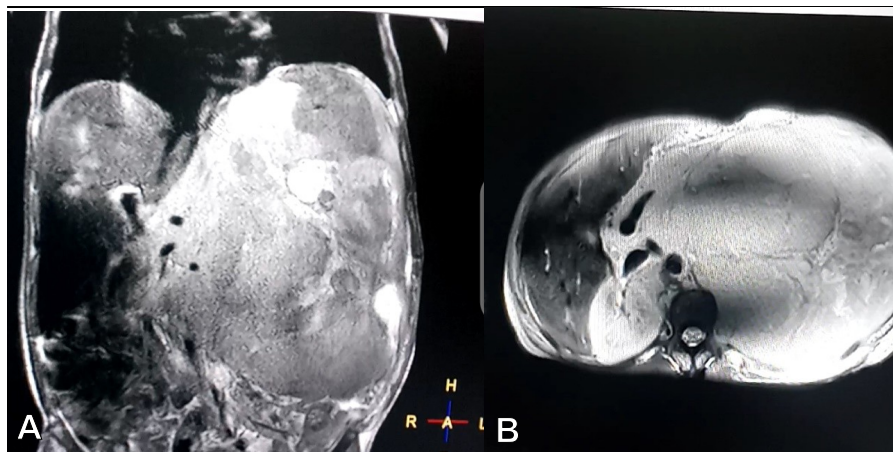


Figure 2: Abdominal magnetic resonance imaging (MRI) showing a large soft tissue retroperitoneal mass; **A:** Coronal view; **B:** Axial view.

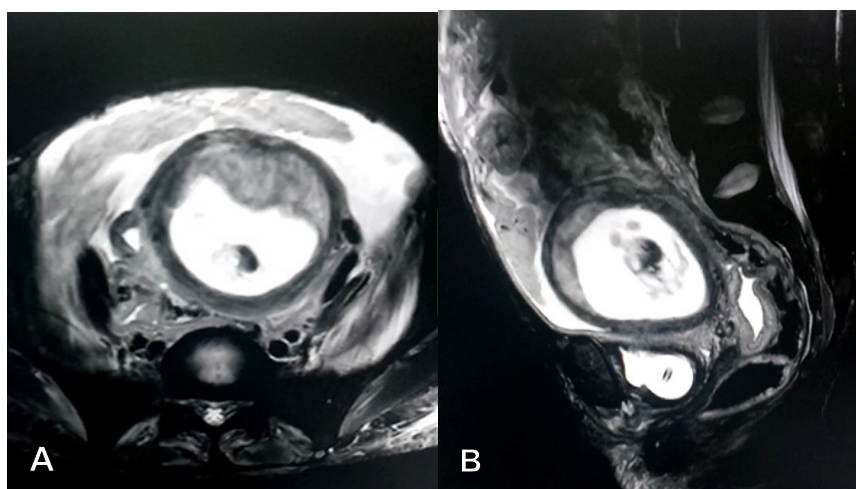


Figure 3: Pelvic MRI showing intrauterine pregnancy; **A:** Coronal view; **B:** Sagittal view.

to liposarcoma during pregnancy have not been determined. However, it is generally accepted that complete surgical tumor resection should increase the curative rate in patients with liposarcomas (2,6). Liposarcomas are staged into four stages, wherein stage one, the tumor is low-grade, small (less than 5cm), and has not metastasized. Stage two, the tumor is of any grade, usually larger than stage one but has not metastasized. Stage three is a high-grade tumor that has not metastasized, and stage four, the tumor of any grade or size, has metastasized (11). The staging was not done in this case.

Surgical resection is the mainstay of treatment for histologic diagnosis and follow-up chemotherapy (6). The patient presented in critical condition, too sick to withstand anesthesia; thus, the diagnosis was made postmortem. The differential diagnoses in patients presenting with retroperitoneal mass include leiomyosarcomas, malignant fibrous histiocytomas, rhabdomyosarcomas, angiosarcomas, neurofibrosarcomas, neuroblastomas, and pheochromocytomas (10). In

this case, an impression of neurofibrosarcoma and nephroblastoma was made where the cortisol levels were elevated at 911.2nmol/L (normal reference range 133-507 nmol/L).

Conclusion

Retroperitoneal liposarcomas are rare and often present a diagnostic and treatment challenge. Therefore, a high index of suspicion should be indicated in women who present with abdominal masses. A multidisciplinary team is essential to manage these tumors effectively.

Consent for publication

Informed consent for publication was obtained from the patient.

Acknowledgement

The authors acknowledge the patient for consenting to the publication of this case report.

Declarations

Conflict of interests

The authors declare no conflicts of interest.

Funding

None

References

1. Mullinax JE, Zager JS, Gonzalez RJ. Current diagnosis and management of retroperitoneal sarcoma. *Cancer Control*. 2011 Jul;18(3):177-87. doi: 10.1177/107327481101800305. PMID: 21666580
2. Zhang WD, Liu DR, Que RS, et al. Management of retroperitoneal liposarcoma: A case report and review of the literature. *Oncol Lett*. 2015;10(1):405-409. doi:10.3892/ol.2015.3193
3. Vilanova J.C. (2017) WHO Classification of Soft Tissue Tumors. In: Vanhoenacker F., Parizel P., Gielen J. (eds) *Imaging of Soft Tissue Tumors*. Springer, Cham. https://doi.org/10.1007/978-3-319-46679-8_11
4. Wang PH, Chao HT, Yuan CC. Ovarian tumors complicating pregnancy. *International Journal of Gynaecology and Obstetrics: the Official Organ of the International Federation of Gynaecology and Obstetrics*. 1997 Nov;59(2):145-146. DOI: 10.1016/s0020-7292(97)00210-5
5. Bhatia K, Shiels MS, Berg A, Engels EA. Sarcomas other than Kaposi sarcoma occurring in immunodeficiency: interpretations from a systematic literature review. *Curr Opin Oncol*. 2012 Sep;24(5):537-46. doi: 10.1097/CCO.0b013e328355e115. PMID: 22729152; PMCID: PMC3418441
6. Bonvalot S, Gaignard E, Stoeckle E, et al. Survival Benefit of the Surgical Management of Retroperitoneal Sarcoma in a Reference Center: A Nationwide Study of the French Sarcoma Group from the NetSarc Database. *Ann Surg Oncol*. 2019 Jul;26(7):2286-2293. doi: 10.1245/s10434-019-07421-9. Epub 2019 May 7. PMID: 31065964
7. Tyler R, Wanigasooriya K, Taniere P, et al. A review of retroperitoneal liposarcoma genomics. *Cancer Treatment Reviews*. 2020 Jun;86. 102013. <https://doi.org/10.1016/j.ctrv.2020.102013>
8. Lopes R.I., Machado M., Paz C., et al. Successful outcome of a surgically treated giant retroperitoneal liposarcoma during pregnancy. *Arch Gynecol Obstet* 280,1067 (2009). <https://doi.org/10.1007/s00404-009-1061-9>
9. Huo, DongFang & Liu, Lin & Tang, Yun. (2015). Giant retroperitoneal liposarcoma during pregnancy: A case report. *World journal of surgical oncology*. 13. 145. 10.1186/s12957-015-0555-0
10. Scali EP, Chandler TM, Heffernan EJ, et al. Primary retroperitoneal masses: what is the differential diagnosis? *Abdom Imaging*. 2015 Aug;40(6):1887-903. doi: 10.1007/s00261-014-0311-x. PMID: 25468494. DOI: [10.1007/s00261-014-0311-x](https://doi.org/10.1007/s00261-014-0311-x)
11. Cates JMM. The AJCC 8th Edition Staging System for Soft Tissue Sarcoma of the Extremities or Trunk: A Cohort Study of the SEER Database. *J Natl Compr Canc Netw*. 2018 Feb;16(2):144-152. doi: 10.6004/jnccn.2017.7042. PMID: 29439175