

# Chronic pelvic pain in a postmenopausal patient with a forgotten Lippes loop: a case report

Kinuthia K<sup>1</sup>, Maogoto E<sup>2</sup>, Karuga J<sup>3</sup>

<sup>1</sup>School of Clinical Medicine, Mount Kenya University

<sup>2</sup>Nazareth Mission Hospital, Nairobi, Kenya

<sup>3</sup>Department of Human Physiology, School of Medicine, Kenya Methodist University

**Correspondences to:** Dr. Kelvin Kinuthia. Email: kinuthiakm@yahoo.com

## Abstract

**Introduction:** A calcified endometrial mass is a worrying finding in a postmenopausal patient, warranting urgent intervention. This case highlights an interesting presentation of a Lippes loop that has grown into an endometrial polyp, raising suspicion that it may have been a malignancy.

**Case presentation:** This is a case of a 70 year old multiparous patient who presented with history of chronic pelvic pain. She could not recall insertion of the Lippes loop, and had therefore never sort to have it removed.

**Management and outcome:** The patient underwent total abdominal hysterectomy and bilateral salpingo-oophorectomy. She made a complete recovery, and histology revealed a calcified endometrial polyp.

**Conclusion:** The Lippes loop is no longer inserted and is becoming a rare find in the practice of gynaecology. This case was an usual presentation of a Lippes loop, as the endometrial polyp had grown around the Lippes loop giving the impression of a calcified endometrial lesion.

**Key words:** Lippes loop, Endometrial polyp, Endometrial cancer

## Introduction

The Lippes loop was a popular intrauterine contraceptive that gave way to the copper device in the 1990s. Older patients may still have the Lippes loop *in situ*, having forgotten its insertion. As the Lippes loop is easily visualized on sonography due to its distinct shape, a calcified endometrial mass in a postmenopausal woman often raises suspicion of presence of malignancy. While it is easy to evaluate such masses in some settings, resource poor centers must do the best they can with what is available. While not all calcified intrauterine masses are malignant, a high index of suspicion is warranted (1) and expedited management is indicated (2).

## Case report

We present the case of a 70 year old, Para 7+0, postmenopausal patient, who presented with a long-standing history of lower abdominal discomfort. The pain was not localized and was described as a generalized sharp pain affecting the whole lower abdomen. The pain was radiating to the left hip joint and was described as sharp. She did not have any post coital bleeding or per vaginal discharge. She could not recall when her menopausal transition had been. She was hypertensive on medication but was not obese. The patient did not recall when the Lippes loop had been inserted, and therefore had never seen a health worker to have it removed. She had seven vaginal deliveries

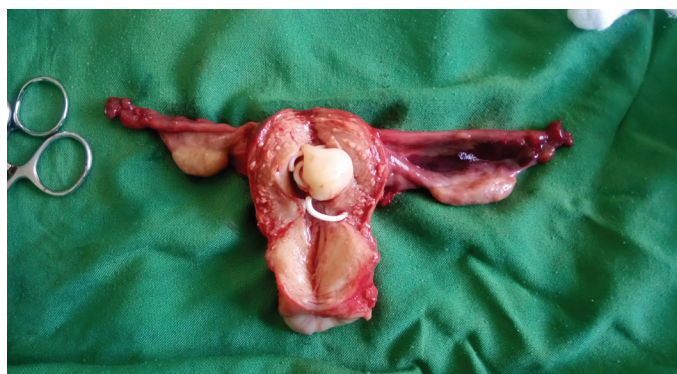and the last was 30 years prior to her admission. She did not have previous history of surgery. Cervical screening was reported as normal. She did not report any family history of endometrial malignancy.

At admission, she was in fair general condition, and her blood pressure was well controlled and within normal range. She did not have any palpable lymphadenopathy in the cervical, axillary or inguinal regions. There was no palpable suprapubic mass on abdominal examination. On pelvic exam, the cervix was grossly normal and the uterus was small, firm and mobile. There was no adnexal mass and no areas of tenderness. Two-dimensional sonography revealed a normal sized uterus with a calcified endometrial mass. The intrauterine device was not visualized, and as the patient had not reported it prior to imaging, the radiologist could not report on its presence. A sonographic conclusion of a calcified uterine fibroid was made. The presence of a calcified endometrial mass in a 70 year old post-menopausal patient raised our suspicion. Saline infusion sonography was not attempted.

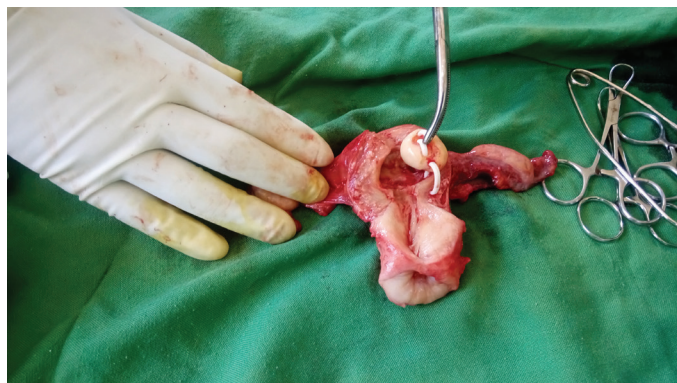
A decision was made to take the patient to theater for total hysterectomy, salpingo-oophorectomy and exploration. Intra-operatively, a normal sized (for age) uterus, was found with grossly normal ovaries and fallopian tubes bilaterally. No para-aortic lymph nodes were palpable and the omentum and gut was grossly normal. Hysterectomy and bilateral salpingo-oophorectomy was done. The specimen was excised

and noted to have a calcified mass that had grown around a forgotten Lippes loop (Figures 1 and 2). The patient made an unremarkable recovery and was discharged on the third post-operative day.

**Figure 1:** A dissected uterus showing a calcified polyp that has grown into a Lippes loop



**Figure 2:** Gentle traction on the Lippes loop revealed the pedicle holding the polyp. Note how the polyp is completely encircling the Lippes loop



The histology report for the specimen reported as normal histology of the cervix, fallopian tubes and ovaries. An endometrial polyp with numerous dilated glands was noted to have overgrown the Lippes loop. There were no features of malignancy.

The patient was counselled on the histology report and is currently on routine care and follow up at the gynaecology clinic.

## Discussion

Lippes loop, an effective method of family planning, was invented in the 1960s by Dr. Jack Lippes (3), and was used until the 1990s. It was used as long term contraception (4) and for this reason amenable to being forgotten. Moreover, retaining the Lippes loop for long was not found to have negative health impact (5). In some studies, no causal effect between leaving the Lippes loop after menopause and development of endometrial cancer was found (3).

The patient in this case report fit the profile of those at risk of developing endometrial cancer based on her multiparous status (6), being hypertensive (7) and postmenopausal. The finding of a calcified mass in the

endometrium, which later turned out to be a polyp, raised the suspicion of the primary health provider. Fortunately, only 4% of endometrial polyps undergo malignant change (8). Ideally, in this case, less drastic measures would have sufficed in her management. Up to 5% of postmenopausal women with endometrial polyps have a diagnosis of premalignant or malignant changes made at histology (9). Having all this in mind, the primary surgeon opted to perform a hysterectomy and bilateral salpingo-oophorectomy. Indeed, similar case reports of patients who had Lippes loop and a polyp have been published (10).

Imaging modalities have improved over the years, making it easier to pick out endometrial polyps. In the reproductive age group, two-dimensional sonography is sufficient to give reassurance on the endometrial mass visualized (11). However, in this case, the Lippes loop could not be properly visualized as it was obscured by the calcified polyp. Hysterectomy and bilateral salpingo-oophorectomy was performed in this case due to high index of suspicion (12).

## Conclusion

In conclusion, not all polyps in postmenopausal women are malignant, though a high index of suspicion is warranted in cases such as this. The retained Lippes loop was an interesting and unexpected finding. Gynecologist practitioners should be on the look out for such unexpected encounters.

## References

1. Litta P, Di Giuseppe J, Moriconi L, Delli Carpini G, Piermartiri MG and Ciavattini A. Predictors of malignancy in endometrial polyps: a multi-institutional cohort study. *Eur J Gynaecol Oncol [Internet]*. 2014 [cited 2018 Mar 19];**35**(4):382–6. Available from: <http://www.ncbi.nlm.nih.gov/pubmed/25118478>.
2. Ricciardi E, Vecchione A, Marci R, Schimberni M, Frega A, Maniglio P, et al. Clinical factors and malignancy in endometrial polyps. Analysis of 1027 cases. *Eur J Obstet Gynecol Reprod Biol [Internet]*. 2014 Dec [cited 2018 Mar 19];**183**:121–4. Available from: <http://www.ncbi.nlm.nih.gov/pubmed/25461364>.
3. Thomsen RJ and Rayl DL. Dr. Lippes and his loop. Four decades in perspective. *J Reprod Med [Internet]*. 1999 Oct [cited 2017 May 18];**44**(10):833–836. Available from: <http://www.ncbi.nlm.nih.gov/pubmed/10554741>.
4. Sinha M, Rani R, Gupta R, Chand K and Kaur G. Lippes Loop inserted 45 years back: The dilemma to remove it or leave it *in situ*. A case report with review of literature. *J Clin Diagn Res [Internet]*. 2015 Apr [cited 2017 May 18];**9**(4):QE01-5. Available from: <http://www.ncbi.nlm.nih.gov/pubmed/26023607>.
5. Aniulienė R and Aniulis P. Lippes loop intrauterine device left in the uterus for 50 years: case report.

- BMC Womens Health [Internet]*. 2014 Dec 15 [cited 2017 May 18];**14**(1):97. Available from: <http://www.ncbi.nlm.nih.gov/pubmed/25128379>.
6. Wu Q-J, Li Y-Y, Tu C, Zhu J, Qian K-Q, Feng T-B, et al. Parity and endometrial cancer risk: a meta-analysis of epidemiological studies. *Sci Rep [Internet]*. 2015 Nov 16 [cited 2017 Jun 8];**5**(1):14243. Available from: <http://www.ncbi.nlm.nih.gov/pubmed/26373341>.
  7. Aune D, Sen A and Vatten LJ. Hypertension and the risk of endometrial cancer: a systematic review and meta-analysis of case-control and cohort studies. *Sci Rep [Internet]*. 2017 Apr 7 [cited 2017 Jun 8]; **7**:44808. Available from: <http://www.ncbi.nlm.nih.gov/pubmed/28387226>.
  8. Steiner E, Juhasz-Bösz I, Emons G, Kölbl H, Kimmig R, Mallmann P, et al. Transvaginal ultrasound for endometrial carcinoma screening - Current evidence-based data. *Geburtshilfe Frauenheilkd [Internet]*. 2012 Dec [cited 2017 Aug 30];**72**(12):1088–91. Available from: <http://www.ncbi.nlm.nih.gov/pubmed/25278620>.
  9. Lee SC, Kaunitz AM, Sanchez-Ramos L and Rhatigan RM. The oncogenic potential of endometrial polyps. *Obstet Gynecol [Internet]*. 2010 Nov [cited 2017 Jun 8];**116**(5):1197–205. Available from: <http://www.ncbi.nlm.nih.gov/pubmed/20966706>.
  10. Tracey Kay RA, Keay SD and Miller P. Diagnosed on removal of an IUD stage Ia endometrial carcinoma. *J Fam Plann Reprod Heal Care [Internet]*. 2017 [cited 2017 May 18]; Available from: <http://jfrhc.bmj.com/content/27/2/99>.
  11. Goldberg Y, Lavie O, Mandel R, Kaufman Y, Segev Y and Auslender R. Two-dimensional sonographic evaluation of endometrial polyps - parameters that are reassuring. *Gynecol Obstet Invest [Internet]*. 2016 [cited 2017 Jun 8];**81**(4):359–362. Available from: <http://www.ncbi.nlm.nih.gov/pubmed/27255414>.
  12. Lachance JA, Darus CJ and Rice LW. Surgical management and postoperative treatment of endometrial carcinoma. *Rev Obstet Gynecol [Internet]*. 2008 [cited 2017 Aug 30];**1**(3):97–105. Available from: <http://www.ncbi.nlm.nih.gov/pubmed/19015760>.