

# HIGH PREVALENCE AND SEVERITY OF POSTPARTUM RETINOVASCULAR CHANGES FOLLOWING PRE- ECLAMPSIA WITH SEVERE FEATURES COMPARED TO NORMAL PREGNANCY.

## Authors

<sup>1</sup>Ayumba A; <sup>1</sup>Ogutu O; <sup>1</sup>Osoti A; <sup>1</sup>Nyamai L; <sup>1</sup>Kihara AB; <sup>1</sup>Kireki O; <sup>1</sup>Gwako GN; <sup>2</sup>Koigi PK; <sup>1</sup>Kosgei RJ; <sup>1</sup>Kilonzo MK; <sup>1</sup>Odawa FX; <sup>1</sup>Ndavi PM

## Institutional Affiliation

1. The University of Nairobi,
2. The Nairobi Hospital

**Correspondence:** ayumbaalb@gmail.com

**Key words:** Retinovascular changes; postpartum; pre-eclampsia; Kenyatta National Hospital

## ABSTRACT

**Background:** Hypertensive retinopathy complicates about 40-100% of pregnancies with hypertensive disorders and its severity worsens with progression of hypertension.

Reactive retinal vessel changes demonstrably also mirror cardiovascular changes in the course of normal pregnancy. There is low utility of fundoscopy in assessing target organ damage and prognosis in pre-eclampsia in low resource setting.

**Objective:** To compare postpartum maternal retinovascular (RV) findings between pregnancies complicated with preeclampsia with severe features (PES) and normal pregnancies at Kenyatta National Hospital (KNH).

## Methodology:

**Design:** Comparative cross-sectional study conducted between May 2017 and March 2018.

**Setting:** KNH, a regional Teaching and Referral hospital.

Study population: Sixty-five women within 72 hours postpartum without preexisting ocular or medical comorbidities following normal pregnancy (n=35) or pregnancies complicated with PES (n=30).

**Data collection:** Participants were interviewed on sociodemographic and reproductive health characteristics and clinical parameters obtained from medical records. Visual acuity assessment was done using a portable LogMAR chart and non-mydratic fundus photography used for retinovascular evaluation. RV changes were graded using Keith Wagner grading.

**Data analysis:** Postpartum retinovascular findings and severity grades were analyzed and presented as percentages and compared between the two groups using Chi square or Fisher's exact test. Odds ratios (OR) of retinovascular changes following pre-eclampsia compared to normal pregnancy was estimated. A p value of <0.05 and 95% confidence interval (CI) that doesn't include the null value were considered significant.

**Results:** Overall prevalence of hypertensive retinovascular change was 90.8% (83.3% in PES versus 97.1% in normal pregnancies). We found statistically significantly greater odds, OR 5.05 CI (0.93, 27.6) of severe retinovascular changes after pregnancies complicated with PES (p=0.045).

**Conclusion:** There is high but comparable prevalence of maternal retinovascular changes within 72 hours postpartum after pregnancies complicated with PES or normal pregnancy. PES is associated with greater odds of postpartum retinovascular changes Compared to normal pregnancies.

## INTRODUCTION

Pre-eclampsia and eclampsia complicates about 2-8% of pregnancies (1). The incidence at Kenyatta National Hospital (KNH) is almost twice the national incidence (Kenya) i.e.3.6% for pre-eclampsia and 2.4% for eclampsia (2) (3). Pre-eclampsia is a multisystemic disease with end organ damage including the retina. Overall, 40-100% of women with hypertensive disorders in pregnancy develop hypertensive retinopathy yet only 25-50 % present with visual symptoms (4). The severity of retinovascular changes worsens with severity of hypertensive disease (5-7). The fundus provides a unique site to study micro vascular changes making fundoscopic examination useful in assessing disease progression. Limited data suggests reactive physiologic changes of retinal vessels in response to cardiovascular changes in normal pregnancies (8)(9). The most common finding is arteriolar attenuation but serious ocular lesions can also occur including acute ischemic optic neuropathy, macula tear, central serous retinopathy, retinal detachment, central retinal vein occlusion, retinal arteriole occlusion and choroidal ischemia (13). There is no recent local study done using digital fundus photography (5). Higher grades of retinal changes have higher association with cardiovascular events e.g. stroke and coronary heart disease. Generalized and focal retinal arteriolar narrowing is reportedly a predictor of the risk of hypertension in normotensive people (6).

The objective of this study was to compare prevalence and severity of retinovascular changes in the early postpartum period in the contexts of pre-eclampsia with severe features (PES) and normal pregnancy.

## METHODOLOGY

**Design:** Cross-sectional study in which women in the early postpartum period were evaluated for retinovascular changes, 30 following PES and 35 following normal pregnancy.

**Setting:** The postnatal wards and the medical outpatient clinic between May 2017 and March 2018 at KNH, the largest tertiary referral hospital in Kenya. Each month there are about 1700 deliveries at KNH. High risk mothers receive multidisciplinary

care including ophthalmology review. RV evaluation is not routinely done but is available if required.

**Study population:** Women with a clinical diagnosis of pre-eclampsia with severe features or normal pregnancy were approached, screened and enrolled within 72 hours postpartum if eligible. We excluded patients known to have diabetes, chronic hypertension, chronic renal disease, cardiac disease, systemic vascular diseases and those with prior history of eye trauma or surgery.

**Sample size:** We estimated that a sample size of 32 women per group would provide 80% power to detect a 35% difference in prevalence in retinopathy between women with PES (70%) versus normal pregnancies (35%) at 95% significance.

**Data variables:** The outcome variables were prevalence and severity of retinovascular changes, while exposure variables were status of pregnancy defined as normal or having PES using standard clinical diagnostic criteria. Retinovascular changes included generalized arteriolar or focal arteriolar narrowing, retinal hemorrhages, retinal detachment, exudates and presence of papilledema. Classification was done using the Keith Wagner (KW) grading as shown in box 1. Severe features of pre-eclampsia included: Blood pressure equal to or greater than 160/110mmhg, platelet count <100000 / ul, progressive renal insufficiency, impaired liver function, pulmonary edema, cerebral and visual functions. Eclampsia is defined as new onset grand mal seizures in a woman with pre-eclampsia.

**Grade 1:** Mild generalized arterial attenuation, particularly of small branches

**Grade 2:** More severe Grade 1 + focal arteriolar attenuation

**Grade 3:** Grade 2 + hemorrhages, hard exudates, macular & retinal edema, cotton wool spots.

**Grade 4:** Grade 3+ optic disc swelling (papilledema)

### Box 1. Keith Wagner Grading

**Study procedure:** Study participants were interviewed on socio-demographic, past medical and ocular history. Visual acuity assessment using a portable LogMAR chart and fundus evaluation by

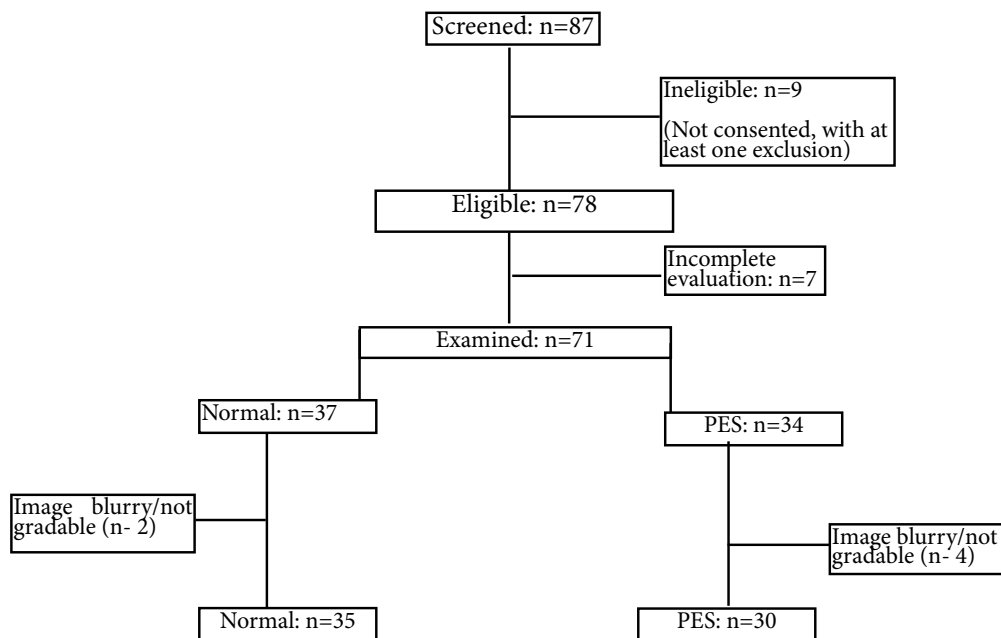


Figure 1: Flow chart.

non-mydriatic fundus camera was then conducted at the medical outpatient clinic by an optometrist.

An ophthalmologist together with the principal investigator reviewed the images and classified the retinovascular findings as per the KW grading for each eye (box 1). The highest KW grade for either eye was used to classify the retinovascular change for that affected patient. Incomplete evaluation was considered when participants were interviewed but not examined. Blurry images with inability to

visualize the fundus were classified as not gradable.

**Data analysis:** Data was entered into an excel database and analyzed using statistical program for social science (SPSSR) version 22 software package. Baseline socio- demographic and reproductive health characteristics were compared between the normal and PES using Chi square test of independence. Prevalence of retinovascular changes (KW 0 versus KW1-4) and its severity (KW 1-3 versus KW4) were compared between normal and PES using Chi

**Table 1: Baseline socio-demographic and obstetric characteristics of the study participants**

Characteristics		PES n (%)	Normal n (%)	p-value
<b>Age group</b>	16-25years	7 (23.3)	14 (40.0)	0.352
	26-35years	17 (56.7)	15 (42.9)	
	36-45years	6 (20.0)	6 (17.1)	
<b>Level of Education</b>	Primary	8 (26.7)	11 (32.4)	0.514
	Secondary	12 (40.0)	16 (47.1)	
	Post-Secondary	10 (33.3)	7 (20.6)	
<b>Parity</b>	One	12 (40.0)	12 (35.3)	0.698
	>one	18 (60.0)	22 (64.7)	
<b>Gestation age at delivery (weeks)</b>	≤34	12 (40.0)	3 (8.6)	<b>0.002</b>
	35-37	7 (23.3)	5 (14.3)	
	>37	11 (36.7)	27 (77.1)	
<b>Visual acuity (Left)</b>	Normal	21 (70.0)	28 (80.0)	0.351
	Not normal (>0.2)	9 (30.0)	7 (20.0)	
<b>Visual acuity (Right)</b>	Normal	25 (83.3)	27 (77.1)	0.534
	Not normal (>0.2)	5 (16.7)	8 (22.9)	

square or Fisher’s exact test as appropriate. Odds ratios (OR) for retinovascular changes and severity and the corresponding 95% confidence interval were estimated. P value <0.05 was considered significant.

**Ethics:** Approval was obtained from the Kenyatta National Hospital/ University of Nairobi ethical review committee (P663/09/2016). Written and verbal informed consent were sought from each participant. Visual acuity and fundoscopy were performed at no cost to the participants.

**RESULTS**

Of the 87 women approached, 78 (74%) consented and 71 (91%) underwent complete evaluation. A total of 65 (92%) women were included in the final analysis, 30 (46%) in the PES group and 35 (54%) in the normal pregnancy group as shown in Figure 1.

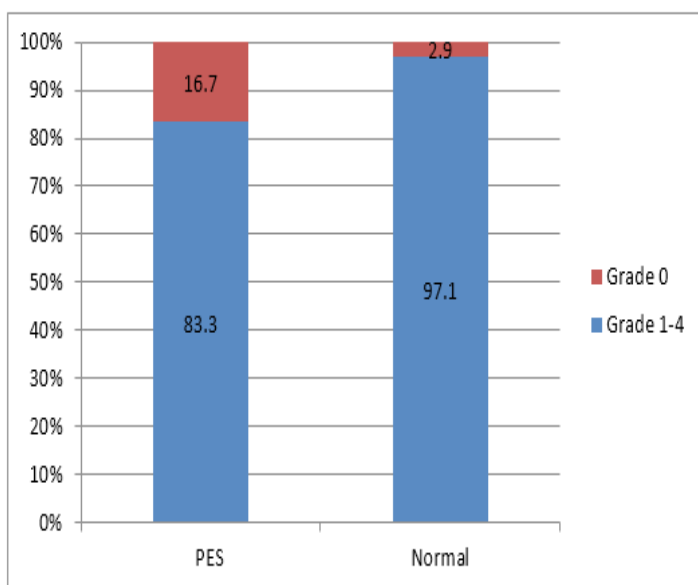
The baseline socio-demographic and obstetric characteristics of the study participants are summarized in table 1. The mean age was 29 years.

Almost 75% had secondary or higher level of education and up to two thirds of the participants were multiparous. Compared to normal pregnancy, women with PES were more likely to deliver at ≤34 weeks gestation (40% vs. 8.6% respectively). Women with normal pregnancies compared to PES were more likely to deliver at ≥37 weeks (77% vs. 36.7% respectively). Visual acuity >0.2 on the LogMAR chart was considered abnormal, which occurred in less than 30% for either eye and was similar between the two groups. There was significant association between gestational age at delivery and severe pre-eclampsia (p=0.002) with those with PES likely to deliver at <34 weeks.

The prevalence and severity of retinovascular changes in normal pregnancies and pregnancies with pre-eclampsia with severe features is shown in Table 2. The overall prevalence of retinovascular (RV) changes within 72 hours postpartum was

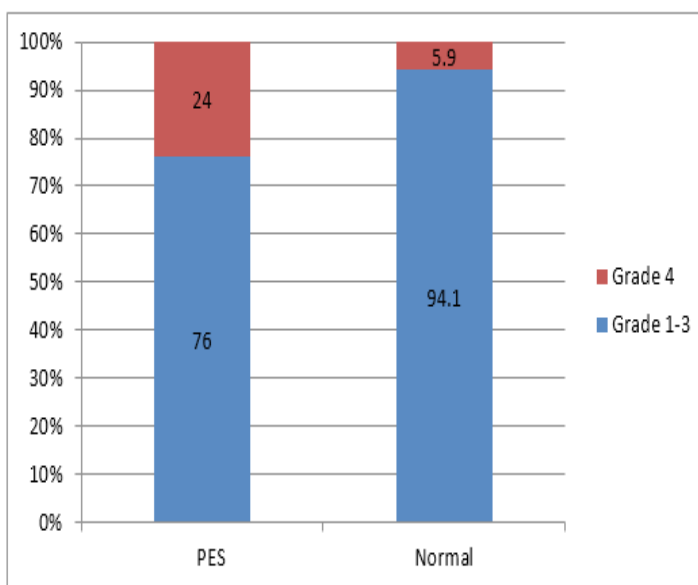
**TABLE 2:- Prevalence and severity of RV changes in PES and Normal pregnancy**

	KW grade prevalence				KW grade severity			
	orGrade 0 n(%)	Grade 1-4 n(%)	Odds ratio (95% C.I)	P value	Grade 1-3 n(%)	Grade 4 n(%)	Odds ratio (95% C.I)	P-value
Normal	1(2.9)	34 (97.1)	0.15 (0.02, 1.34)	0.055	32 (94.1)	2 (5.9)	5.05 (0.93, 27.6)	<b>0.045</b>
PES	5(16.7)	25 (83.3)			19 (76)	6 (24)		



**Figure 2: Prevalence of abnormal postpartum maternal retinal findings.**

PES- pre-eclampsia with severe features  
Normal- normal pregnancy group



**Figure 3: Severity of Keith Wagner grades in PES compared to normal**

PES- pre-eclampsia with severe features group  
Normal- normal pregnancy group

90.8% and was comparable between the two groups. The odds ratio (OR) of retinovascular changes was insignificantly lower in the PES group (OR 0.15, 95% CI 0.02-1.34).

The prevalence of severe retinovascular changes (KW 4) was higher in the PES (24%) compared to normal pregnancy group (5.9%) as shown in Figure 3. The odds ratio of having severe retinovascular changes was 5-fold greater among the PES group compared to the normal pregnancy group. However, this increase was not statistically significant. (OR 5.05, 95% C.I [0.93-27.6], P=0.05) as shown in Table 2.

## DISCUSSION

This study found a comparably high prevalence of retinovascular changes in the early postpartum period in both the normal (97%) and PES (83%) groups. Higher prevalence of RV changes has been reported (7). A local study in this setting done 25 years ago reported 60% occurrence of ocular fundus changes in the left eye and 58% in the right eye in patients with pre-eclampsia/ eclampsia (5). However, these studies were limited to pregnancy complicated with hypertension and did not have a comparative group of normal pregnancy. The prevalence of RV changes in early postpartum period following a normal pregnancy was very high. Measurable retinal arterial narrowing has previously been demonstrated to occur in uncomplicated pregnancies (8) (9). Retinal vessel changes mirrors the rise and fall of mean arterial pressure throughout gestation in normal pregnancy returning to baseline at 6 months postpartum (10). Vasodilators (nitric oxide, prostacyclin, prostaglandins) and vasoconstrictors (Angiotensin II) have been postulated to play a role in these temporal changes. We found that KW grade 3 retinovascular change was the most prevalent in both normal (88.6%) and PES (60.0%) patients in current study. Grade 2 overall was 2% and grade 4 overall was 12%, no grade 1 retinal vessel change was recorded. Previous studies found a predominance of grade 1 retinopathy of between 8-52.6% (7) (11) (12). A significant association between retinovascular changes and pregnancy complicated with PES was reported in this setting. KW Grade 4 retinopathy was significantly higher in

the PES group than in the normal pregnancy group. This is consistent with other studies on hypertensive retinopathy in pregnancy induced hypertension that reported positive association between severity of retinopathy and hypertension. (11) (13) (7) (14) (12). Although Rasdi et al, 2011 and Gupta et al, 2008 found no positive association, they notably measured for association based on only blood pressure criteria classification of severity of hypertensive disease.

Our study strengths include being the first study in this setting to use a high definition fundus camera which also has the advantage of eliminating time constraints compared to performing a clinical fundoscopic exam. Digital fundus photography also ensured standardization of findings. In addition, as opposed to other studies that only assessed pregnancy complicated with PES, our study had a normotensive group for comparison. The inclusion of the normal pregnancy group also provides invaluable baseline data for larger prospective studies.

The limitations of this study are largely due its cross-sectional nature. We limited our study to the first 72 hours postpartum and had no retinal vessel evaluation from antepartum to postpartum period which could describe any progressive changes in RV findings. Having limited our study to immediate postpartum, when pregnancy and labour related changes have not resolved, we could have found higher prevalence of retinovascular changes in both groups. This high prevalence could have lowered power to detect group differences. However, this study provides baseline data that can inform future longitudinal studies.

## CONCLUSION

In the immediate postpartum period, the prevalence of retinovascular changes was comparably high after normal pregnancies and among pregnancies complicated with pre-eclampsia with severe features (PES). The odds of severe retinovascular changes are greater for pregnancy complicated with PES in comparison to normal pregnancy.

**Acknowledgements:** The research leading to this publication was conducted through an adaptation of the Structured Operational Research and Training Initiative (SORT IT), a global partnership led by

the UNICEF/UNDP/World Bank/WHO Special Programme for Research and Training in Tropical Diseases (WHO/TDR). The model is based on a course developed jointly by the International Union Against Tuberculosis and Lung Disease (The Union) and Médecins sans Frontières.

The specific SORT IT programme which resulted in this publication was developed and implemented by the University of Nairobi, Department of Obstetrics and Gynaecology, Nairobi, Kenya with financial support from WHO/TDR.

I thank my supervisors for the patience and guidance in preparing this paper, as well as my family for providing the necessary atmosphere until the completion of this work

**Funding:** This study was self-funded.

**Authorship:** All authors contributed to the paper.

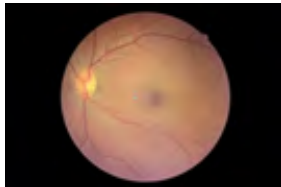## REFERENCES

1. Duley L. The global impact of pre-eclampsia and eclampsia. *Semin Perinatol.* 2009;33(3):130-7.
2. Abalos E, Cuesta C, Carroli G, Qureshi Z, Widmer M, Vogel JP, et al. Pre-eclampsia, eclampsia and adverse maternal and perinatal outcomes: a secondary analysis of the World Health Organization Multicountry Survey on Maternal and Newborn Health. *BJOG.* 2014;121Suppl:14–24.
3. John K, Machoki JM, Olakhi O. A review of maternal and perinatal outcomes of pregnancies complicated by hypertensive disease at Kenyatta National Hospital. UON, MMed Dissertation (Unpublished data), 2005: 1 - 34.
4. Mackensen F, Paulus WE, Max R, Ness T. Ocular changes during pregnancy. *Dtsch Arztebl Int.* 2014;111(33–34):567–76.
5. Ahenda J, Adala H.S, Bhajji. Ocular manifestation in preeclampsia and eclampsia. UON, MMed Dissertation (Unpublished data), 1991: 1 - 49.
6. A Grosso, F Veglio, M Porta, F M Grignolo TYW. Hypertensive retinopathy revisited: some answers, more question. *Br J Ophthalmol.* 2005;89:1646–54.
7. Bhandari A, Bangal S, Gogri P. Ocular fundus changes in pre-eclampsia and eclampsia in a rural set-up. *J Clin Ophthalmol Res.* 2015;3(3): 139.
8. Li L, Cheung CY, Ikram MK, Gluckman P, Meaney MJ, Chong Y, et al. Blood Pressure and Retinal Microvascular Characteristics Growing Up in Singapore Towards Healthy Outcomes (GUSTO) Study. 2012:(Md 3).
9. Abu SK. The eye and visual system in the preeclampsia/eclampsia syndrome: What to expect? *Saudi J Ophthalmol.* King Saud University; 2013;27(1): 51–53.
10. Lupton SJ, Chiu CL, Hodgson LAB, Tooher J, Lujic S, Ogle R, et al. Temporal changes in retinal microvascular caliber and blood pressure during pregnancy. *Hypertension.* 2013;61(4): 880–5.
11. Shah A, Lune A, Magdum R, Deshpande H, Bhavsar D, Shah A. Retinal changes in pregnancy-induced hypertension. *Med J Dr DY Patil Univ.* 2015;8(3): 304.
12. Tadin I, Bojić L, Mimica M, Karelović D, Dogas Z. Hypertensive retinopathy and pre-eclampsia. *Coll Antropol.* 2001;25 Suppl: 77–81.
13. Bakhda RN. Ocular manifestations of Pregnancy Induced Hypertension. *Delhi J Ophthalmol.* 2015;26(2): 88–92.
14. Sembilan N, Jaafar T, Sembilan N, Khor B. Fundus changes in pregnancy induced hypertension. *Int J Ophthalmol.* 2008;5(6): 694-697.

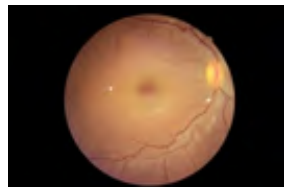\*\*\*\*\*

# POLICY BRIEF

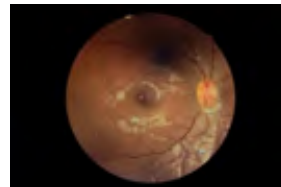
## IS EYE DISEASE BEING IGNORED IN POST-DELIVERY MOTHERS WITH HIGH BLOOD PRESSURE?



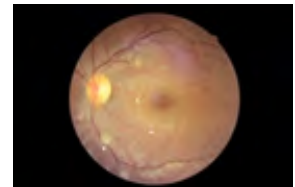Normal Fundus



Increased tortuosity



Macula, retinal edema



Cotton wool spots

### DIGITAL FUNDOSCOPY AND PREGNANCY

Overall, 40- 100% of women with hypertensive disorders in pregnancy develop hypertensive retinopathy yet only 25-50 % present with visual symptoms.<sup>1</sup> Severity of retinovascular changes seem to relate with the severity of pre-eclampsia and eclampsia. Status of retinal arterioles may indirectly reflect the state of the placenta and thus the fetus<sup>2</sup>. On the other hand normal pregnant women have reactive retinal vessel changes that mimic the cardiovascular changes in the course of pregnancy. These changes are thought to be transient and but have even been shown to resolve at about 6 weeks postpartum<sup>4</sup>. Fundoscopy is thus an important mode of assessing target organ damage and magnitude of hypertensive disease progression in mothers with hypertension. It provides a good “window” to study retinal human microvasculature. In our setting, evaluation of retinal changes in patients with PES is not part of our standard routine care. This study has compared prevalence and severity of retinovascular changes in the early postpartum period in the context of pre eclampsia with severe features (PES) and normal pregnancy.

### PRIORITY ACTIONS

1. Develop unit protocols for early evaluation and or immediate transfer for care to minimize long term sequelae.
2. Sensitize caregivers to understand various ocular conditions associated with hypertension in pregnancy and to handle it in a multidisciplinary manner.
3. Avail adequate facilities for definitive tests e.g. optical coherence tomography for suspected serious retinal conditions.

### OUR FINDINGS AT KENYATTA NATIONAL HOSPITAL

1. High prevalence of early postpartum retinovascular changes in both uncomplicated and pregnancies complicated with severe pre-eclampsia with an overall prevalence of 90%.

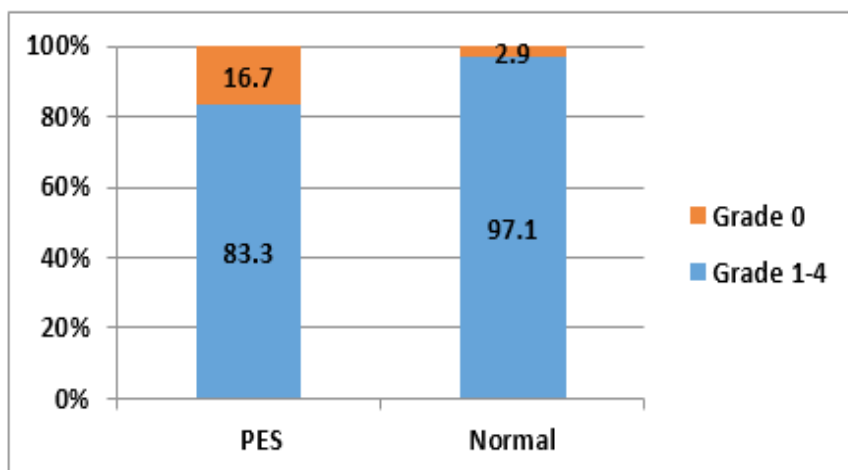
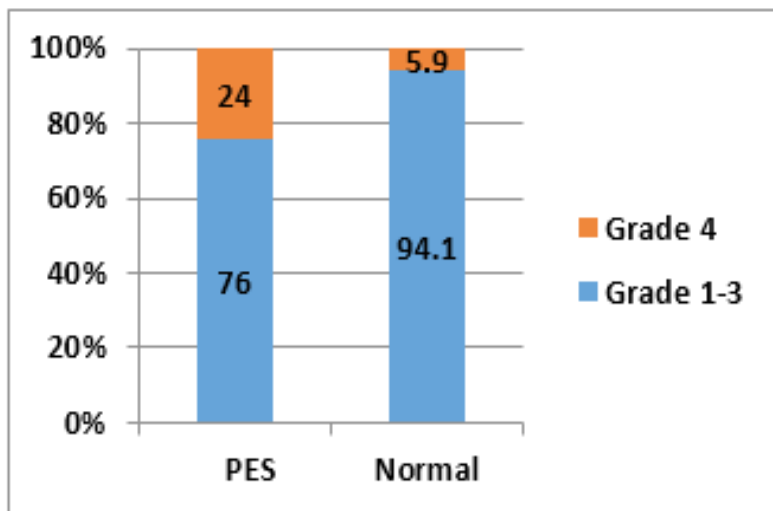


Figure 1: Prevalence of retinovascular changes in pre eclampsia with severe features (PES) compared to normal pregnancy.

2. High prevalence of severe retinovascular changes in pre-eclampsia with severe features group (PES) versus the normal pregnancy group.



**Figure 2: Severity of hypertensive retinovascular changes.**

## LONG TERM IMPLICATIONS

Reduced vision and blindness due to optic atrophy, retinal vessel thrombosis and proliferative retinopathy are recognized ocular manifestations in the long term. New onset cerebral and visual disturbance is among the criterion for diagnosis of pre-eclampsia with severe features. There is currently no precise and widely accepted guideline on diagnosis and management of hypertensive retinal changes in patients with pre eclampsia. Increased risk of cardiovascular events has been associated with higher grades of retinal changes i.e. stroke and coronary heart disease. Generalized and focal retinal arteriolar narrowing has been shown to predict the risk of hypertension in normotensive people<sup>4</sup>. Large prospective observational studies in the local setting may reproduce similar findings. This will allow longitudinal follow up from antepartum to postpartum period.

## REFERENCES

1. Mackensen F, Paulus WE, Max R, Ness T. Ocular changes during pregnancy. *Dtsch Arztebl Int.* 2014
2. Bhandari A, Bangal S, Gogri P. Ocular fundus changes in pre-eclampsia and eclampsia in a rural set-up. *J Clin Ophthalmol Res.* 2015.
3. Lupton SJ, Chiu CL, Hodgson LAB, Tooher J, Lujic S, Ogle R, et al. Temporal changes in retinal microvascular caliber and blood pressure during pregnancy. *Hypertension.* 2013.
4. A Grosso, F Veglio, M Porta, F M Grignolo TYW. Hypertensive retinopathy revisited: some answers, more question. *Br J Ophthalmol.* 2005; 89:1646–54
5. Ayumba A, Omondi O, Osoti A, Nyamai L, Kihara AB, Kireki VO et al. High prevalence and severity of postpartum retinovascular changes following pre-eclampsia with severe features compared to normal pregnancy. *J Obstet Gynecol E Cent Afr,* 2018; 30 (2) :3 - 8

**AUTHORS:** Ayumba A, Ogutu O, Osoti A, Nyamai L, Kihara AB, Kireki O, Gwako GN, Koigi PK, Kosgei RJ, Kilonzo MK, Odawa FX, Ndavi PM

**Acknowledgement:** The research leading to this publication was conducted through an adaptation of the Structured Operational Research and Training Initiative (SORT IT), a global partnership led by the UNICEF/UNDP/World Bank/WHO Special Programme for Research and Training in Tropical Diseases (WHO/TDR). The model is based on a course developed jointly by the International Union Against Tuberculosis and Lung Disease (The Union) and Médecins sans Frontières.

The specific SORT IT programme which resulted in this publication was developed and implemented by the University of Nairobi, Department of Obstetrics and Gynaecology, Nairobi, Kenya with financial support from WHO/TDR.

**CONTACT:** Dr. Ayumba Albert; Email- ayumbaalb@gmail.com; Contact- 0726868932; Address- P.O BOX 15248-00100